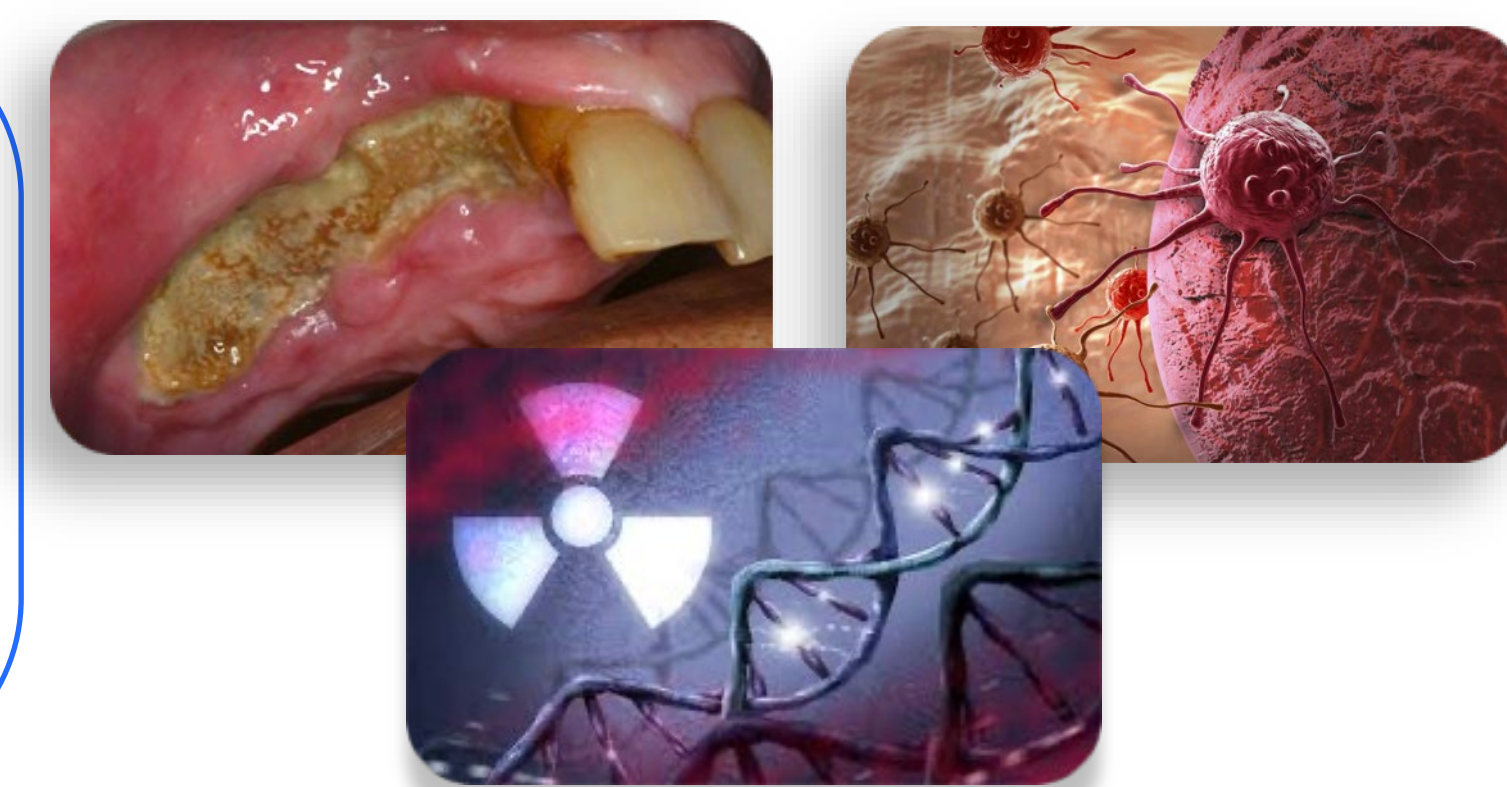




INTRODUCCION

Osteonecrosis is one of the most common consequences in oncology patients treated with radiation therapy after undergoing dental and general surgical treatments due to compromised blood supply, leading to tissue damage and inflammation, as long as they are performed within the irradiated area. These cases are irreversible and painful, adding to the distress and sometimes aggression cancer patients may experience. However, if a patient is diagnosed and needs surgical treatment, the patient requires careful and detailed analysis and studies more than any other case in dentistry. It necessitates preoperative planning and the application of an excellent and appropriate protocol for each patient, depending on the type, stage, and location of the cancer. It is by no means coincidental or random.



METHODS & MATERIALS

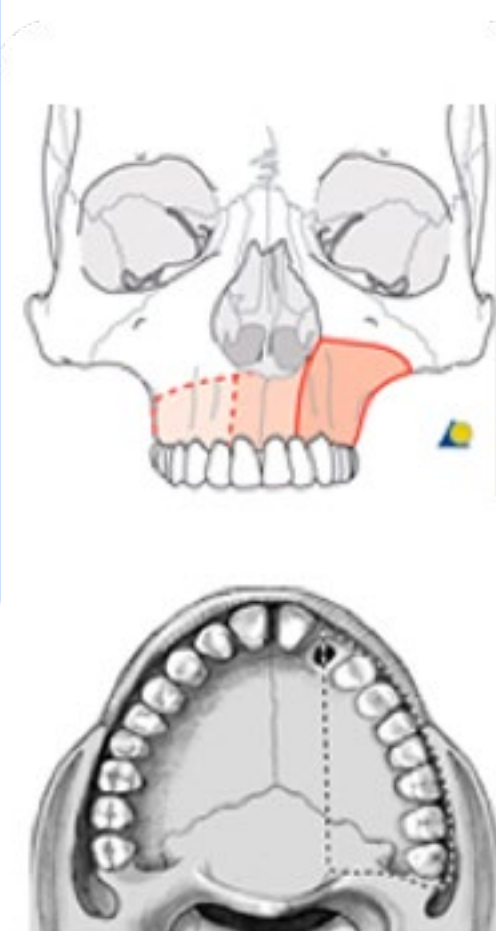
The present study is descriptive type; specifically, it is a case review of a patient diagnosed with squamous cell carcinoma in the left upper maxillary region, treated with radiotherapy. The patient underwent dental surgical treatment, which resulted in maxillary osteoradionecrosis at the Oncology Hospital in Valencia, Venezuela. 2015.

- **Step 1: Diagnosis:** This patient was diagnosed through intraoral and extraoral examinations, X-rays, CT scans, and biopsy.
- **Step 2: Radiotherapy:** The patient was prescribed 12 cycles with a 21-day interval. 11 days after starting the first cycle, without authorization from their treating oncologist, the patient decides to visit a public dental office to have tooth #16 extracted due to mobility.
- **Step 3: Surgical Intervention:** The patient developed maxillary osteonecrosis and tumor expansion due to the surgical dental treatment. As a result, a modified Weber Ferguson maxillectomy was performed, with the construction of a left temporal advancement flap in the skin and muscle plane for the floor of the orbit, total maxillectomy with electrocautery closure, an extension of margins in the left pterygoid, nasopharynx, left orbital cavity, soft palate, and a deltopectoral flap to cover the defect of the left hemispherical skin, closed in layers.

OBJETIVES

- Raise awareness among oncology patients about the potential consequences of dental surgical treatment during radiotherapy and the risk of developing osteonecrosis.
- Facilitate improved communication between physicians and dentists regarding the medical history of oncology patients, promoting comprehensive and coordinated care.

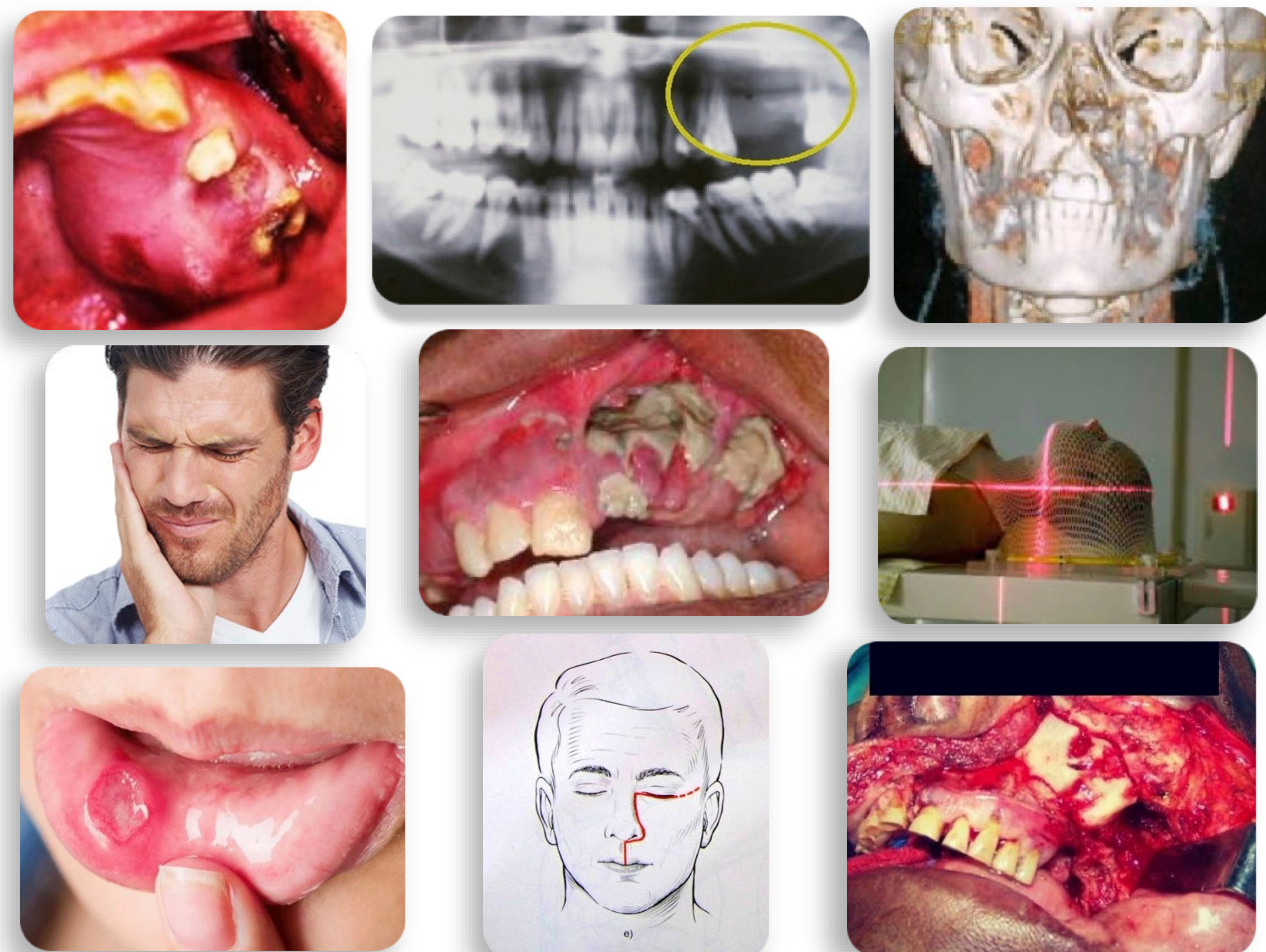MAXILLECTOMY



Maxillectomy is a surgical procedure involving removing part or all of the maxilla (upper jawbone). It is performed to treat conditions such as oral or maxillofacial tumors, maxillary osteonecrosis, and maxillary trauma. The procedure can range from a partial removal to a complete removal of the maxilla. Reconstruction techniques may be used to restore the structure and function of the affected area.

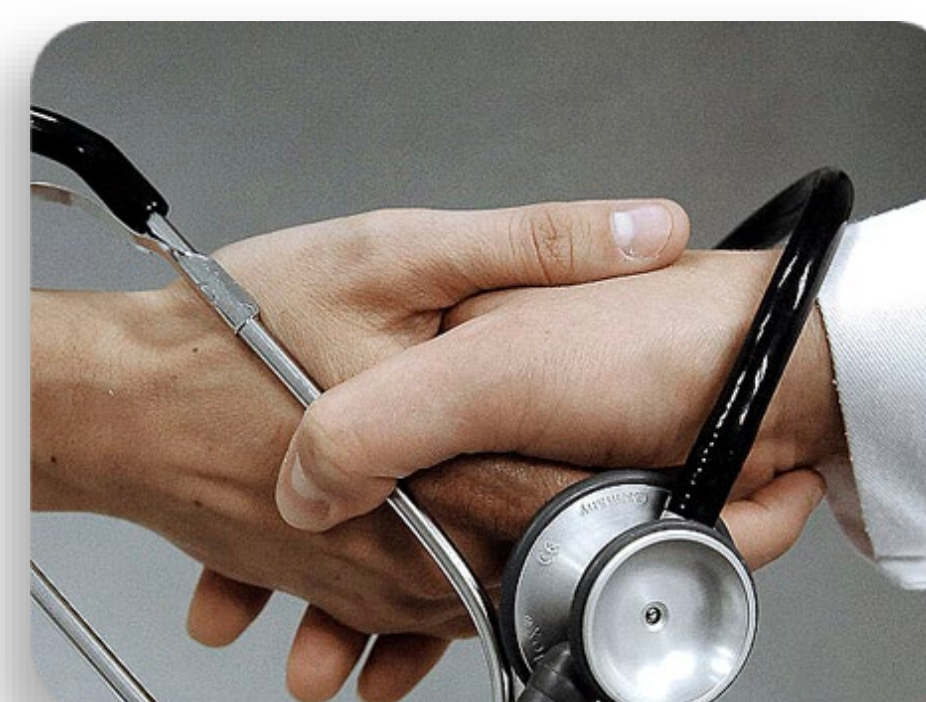
CONSEQUENCES

- **Persistent pain:** The dying bone tissue can cause increased pressure, nerve irritation, and compression, resulting in ongoing pain.
- **Non-healing ulcers:** Ulceration and necrosis of the mucosa with exposed bone, inevitably leading to infection and necrotic bone.
- **Facial deformity:** Maxillary osteonecrosis can cause the collapse of the maxilla, leading to changes in facial appearance such as sunken cheeks, loss of dental support, altered alignment of upper teeth, and impact on overall facial symmetry.
- **Loss of the maxillary bone:** is the gradual or progressive destruction of bone tissue in the maxilla, resulting from avascular necrosis and causing bone death.



RECOMMENDATIONS

- Consider the patient's intraoral and extraoral clinical characteristics, among complementary imaging examinations and biopsy, to establish an accurate diagnosis for oncologic patients. It is crucial to develop an appropriate treatment plan.
- Specialists, in their respective areas, should integrate, work as a team, and convey to the patients the importance of honestly disclosing their health condition.
- Patient Education: Osteoradionecrosis is a potential complication of radiation treatment to the head and neck. Discussing this possibility with patients prior to treatment can help raise awareness and minimize its occurrence.
- Hold conferences to address all the queries concerning the protocol dentists should adhere to in cancer cases, radiotherapy, and dental surgical procedures. This will serve as an effective method to provide clarification and guidance.



CONCLUSION

The specialist dentist in Oncology patients and the Oral or Maxillofacial Surgeon are responsible for establishing controls and follow-up within the multidisciplinary Oncology team. They must work together, performing clinical and radiographic evaluations and monitoring to prevent the early onset of osteoradionecrosis. Any dental surgical procedure should be performed before radiation therapy, prioritizing teeth extraction with poor prognosis. If necessary, a minimum waiting period of one year and a half should be observed before proceeding with surgeries in the area.

